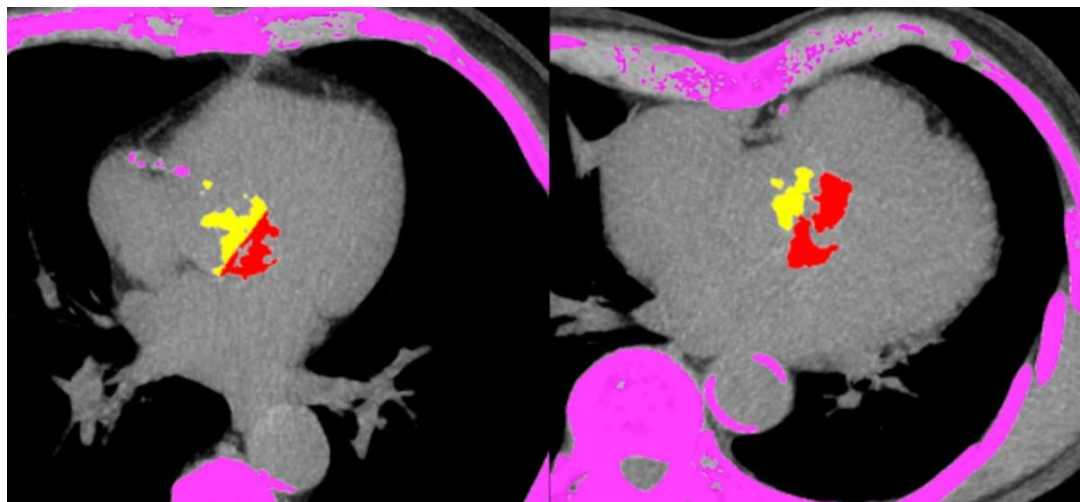
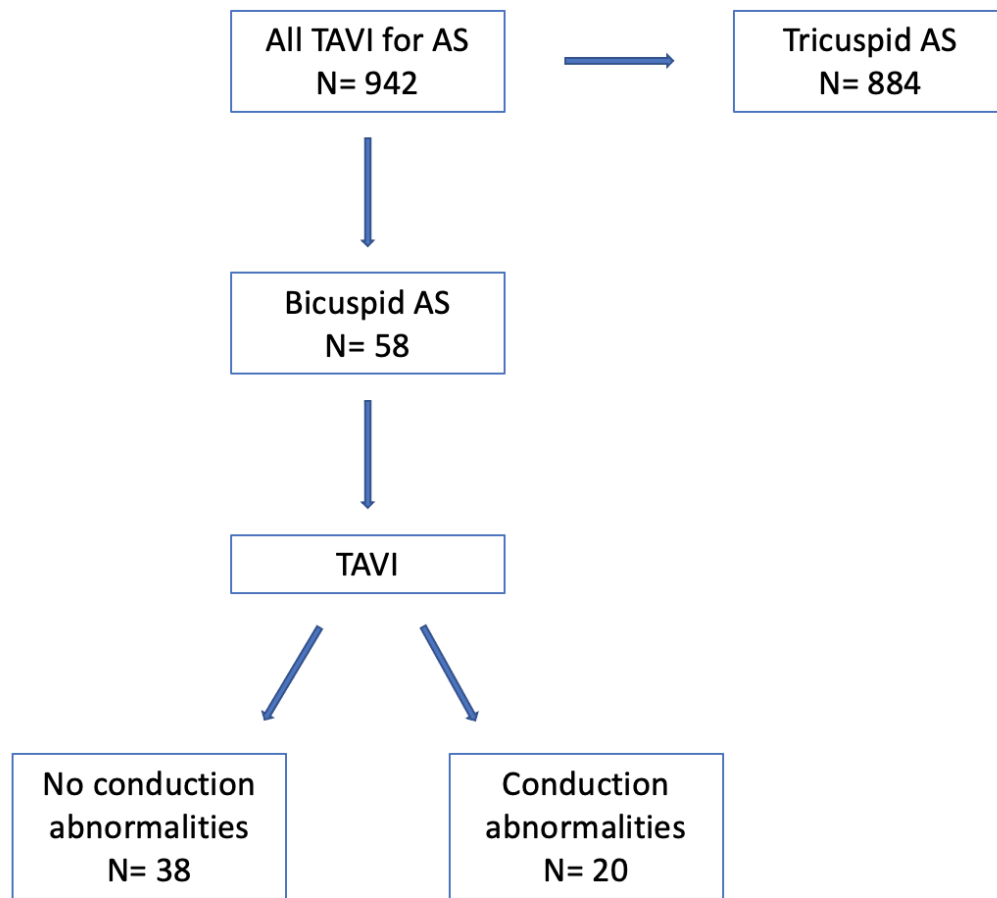


Supplementary figures



Supplementary figure 1: Non-contrast transverse view from the CT scan of two patients. The virtual line used to separate valve calcification adjacent to and opposite the MS can be seen running in a roughly 30-45 degree angle to the anterior-posterior axis of the body.



Supplementary figure 2: Study flow diagram.