


openheart Impact of ultrasound contrast agent during transoesophageal echocardiography on the sizing of the left atrial appendage

Henning Ebelt , Sarah Goetze, Anja Weida, Alexandra Offhaus

To cite: Ebelt H, Goetze S, Weida A, *et al.* Impact of ultrasound contrast agent during transoesophageal echocardiography on the sizing of the left atrial appendage. *Open Heart* 2021;**8**:e001403. doi:10.1136/openhrt-2020-001403

Received 30 July 2020
Revised 19 December 2020
Accepted 9 March 2021

ABSTRACT

Introduction Interventional closure of the left atrial appendage closure (LAAC) has been established as an alternative treatment in patients with atrial fibrillation (AF) and an increased risk of stroke. So far it is unknown whether the use of ultrasound contrast agent (UCA) would influence the correct sizing of the LAA and thereby have an impact on device selection during interventional LAAC.

Methods Between January 2017 and April 2018, 223 transoesophageal echocardiography (TOE) examinations were prospectively performed in adult patients with non-valvular AF (Impact of the use of ultrasound contrast agent on the detection of thrombi in the left atrial appendage during transoesophageal echocardiography (CONDOR) study). LAA was examined both with and without the use of UCA. The following measurements were taken at 0°, 45°, 90° and 135°: diameter of LAA ostium, maximal depth of the LAA, maximal available depth of the LAA orthogonal to the ostial plane and area of the LAA.

Results The use of UCA had no relevant influence on the size determination of the LAA. Additionally, Bland-Altman blots demonstrate a high degree of correlation between the measurements with and without UCA with no evidence for a systematic effect arising from the use of UCA. When comparing the measurements of two independent investigators, the use of UCA rather leads to a higher variability than to an improved precision.

Discussion Despite the fact that the use of UCA during TOE leads to an improved rule out of thrombi, our study shows that there is no advantageous effect of UCA on the size determination of the LAA and should therefore not be used for this purpose.

INTRODUCTION

Atrial fibrillation (AF) is associated with an increased risk of intracardiac thrombus formation and subsequent stroke and systemic embolism. In at least 90% of cases, the underlying thrombi are originating from the left atrial appendage (LAA).^{1,2} Within the last years, interventional LAA closure (LAAC) has been established as an alternative treatment in patients with AF and an increased risk of stroke especially if contraindications regarding the use of oral anticoagulation are

Key questions

What is already known about this subject?

► The interventional occlusion of the left atrial appendage closure is nowadays an alternative treatment strategy for patients with atrial fibrillation (AF) and a high thromboembolic risk if oral anticoagulation is considered contraindicated. Correct size determination of the left atrial appendage (LAA) is of crucial importance in these patients. In previous studies, it has been reported that the use of ultrasound contrast agent (UCA) improves the diagnostic yield of transoesophageal echocardiography (TOE) regarding the detection of thrombi in patients with AF. However, no information is available whether the use of UCA also improves the correct sizing of the LAA.

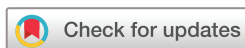What does this study add?

► This study shows that the routine use of UCA in patients with AF does not have an impact on size determination of the LAA. Surprisingly, the use of UCA rather leads to a higher variability than to an improved precision.

How might this impact on clinical practice?

► This study shows that during TOE there is no advantageous effect of UCA on the size determination of the LAA and that UCA therefore should not be used for this purpose.

existing.³ For an optimal procedural result of LAAC, a detailed knowledge of the anatomy and size of the LAA is of crucial importance. In clinical practice, transoesophageal echocardiography (TOE) is the standard imaging modality to evaluate the LAA which nowadays is complemented by CT scan, both to rule out LAA thrombi as well as to select a suitable device for LAAC. We have recently shown in a prospective study (CONDOR) that the use of ultrasound contrast agent (UCA) improves the rule out of LAA thrombi in patients with AF and has a significant impact on the management of these patients if they are scheduled for an interventional procedure.⁴



© Author(s) (or their employer(s)) 2021. Re-use permitted under CC BY-NC. No commercial re-use. See rights and permissions. Published by BMJ.

Department of Medicine II, Catholic Hospital, Sankt Johann Nepomuk, Erfurt, Thüringen, Germany

Correspondence to

Dr Henning Ebelt;
henningebelt@gmail.com

However, so far it has not been reported whether UCA would also have an impact on the determination of the size of the LAA. As UCA can lead to an improved delineation of the endocardial borders, it seems possible that this might translate into effects on the size determination of the LAA during TOE and thereby have an impact especially on device selection during interventional LAAC.

METHODS

The data presented here were acquired as a part of the prospective CONDOR Study ('Impact of the use of ultrasound contrast agent on the detection of thrombi in the left atrial appendage during transoesophageal echocardiography', German Registry of Clinical Trials, DRKS00011716) that has been described before.⁴ Between January 2017 and April 2018, 223 TOE examinations were prospectively performed in adult patients with non-valvular AF. All TOEs were performed according to the clinical standards using a General Electric Vivid E9 (GE, Boston, Massachusetts, USA) equipped with a 3D probe (model 6T), all images were taken using harmonic imaging. Patients received local anaesthesia of the throat with 2% xylocaine pump spray (Aspen Germany GmbH, Munich, Germany) and afterwards 2–5 mg midazolam intravenous (Ratiopharm, Ulm, Germany). LAA was examined both without the use of UCA at 0°, 45°, 90° and 135° at imaging settings used in clinical routine and again after intravenous injection of 1.0 mL of the UCA Sonovue (Bracco International B.V., Amsterdam, The Netherlands). The settings of the echo machine were adjusted for the use of UCA by reducing acoustic power to -32 dB/-28 dB resulting in a mechanical index of 0.04–0.1. If image quality after administration of UCA was not satisfying, a second bolus of 1.0 mL Sonovue could be given. For quantification of the LAA, all TOE loops were stored and analysed by an independent investigator. The following measurements were taken at 0°, 45°, 90° and 135°: diameter of LAA ostium, maximal depth of the LAA, maximal available depth of the LAA orthogonal to the ostial plane and area of the LAA.

Statistical analysis

Statistical data analysis was performed using SPSS Statistics (V.26, SPSS). Differences in frequency of nominally scaled parameters were compared by means of Pearson's χ^2 test. Metric variables are expressed as mean \pm SD and were compared with Student's t-test.

RESULTS

Patient characteristics are given in table 1 (see also Ebel *et al.*)⁴ The dimensions of the LAA as determined with and without the administration of UCA are given in table 2. No relevant differences were seen between the groups for the parameters that were analysed. Additionally, Bland-Altman blots for the quantification of the LAA ostium are given in figure 1 demonstrating a high degree of correlation between the measurements with and without UCA.

Table 1 Characteristics of study patients (N=223)

Parameter	Value
Age (years)	71.3 \pm 9.9
Gender, male	122 (54.7%)
LV-EF (%)	51.7 \pm 14.0
Type of atrial fibrillation	
Paroxysmal	71 (31.8%)
Persistent	123 (55.1%)
Permanent	29 (13.0%)
Hypertension	200 (89.7%)
Diabetes	85 (38.1%)
Previous stroke	31 (13.9%)

See also Ebel *et al.*⁴

LV-EF, left ventricular ejection fraction.

However, there is no evidence of a systematic sizing effect arising from the use of UCA.

In order to determine whether the use of UCA would lead to a higher precision of the quantifications, all

Table 2 Dimensions of the LAA ostium determined by TOE with and without UCA in different standard views (N=223)

	Without UCA	With UCA	P value
0°			
Diameter (mm)	19.4 \pm 5.2	20.2 \pm 4.8	0.056
Max. depth (mm)	25.1 \pm 7.1	25.0 \pm 5.9	0.546
Orthogonal depth (mm)	21.4 \pm 5.8	21.3 \pm 5.5	0.603
Area (mm ²)	385.3 \pm 142.3	391.7 \pm 126.1	0.772
45°			
Diameter (mm)	19.0 \pm 4.2	18.7 \pm 3.9	0.352
Max. depth (mm)	23.9 \pm 5.5	24.3 \pm 5.3	0.359
Orthogonal depth (mm)	19.4 \pm 4.8	19.8 \pm 4.6	0.257
Area (mm ²)	358.3 \pm 118.9	374.3 \pm 109.7	0.025
90°			
Diameter (mm)	18.8 \pm 4.3	19.0 \pm 4.1	0.378
Max. depth (mm)	25.5 \pm 6.0	24.4 \pm 5.1	0.010
Orthogonal depth (mm)	20.3 \pm 5.6	19.9 \pm 4.8	0.309
Area (mm ²)	391.2 \pm 121.8	389.5 \pm 108.3	0.879
135°			
Diameter (mm)	19.3 \pm 5.5	19.1 \pm 5.0	0.700
Max. depth (mm)	22.5 \pm 5.9	22.7 \pm 5.6	0.650
Orthogonal depth (mm)	20.9 \pm 5.9	21.1 \pm 5.8	0.602
Area (mm ²)	364.2 \pm 113.3	379.1 \pm 112.4	0.039

LAA, left atrial appendage closure; P, level of significance (paired t-test); TOE, transoesophageal echocardiography; UCA, ultrasound contrast agent.

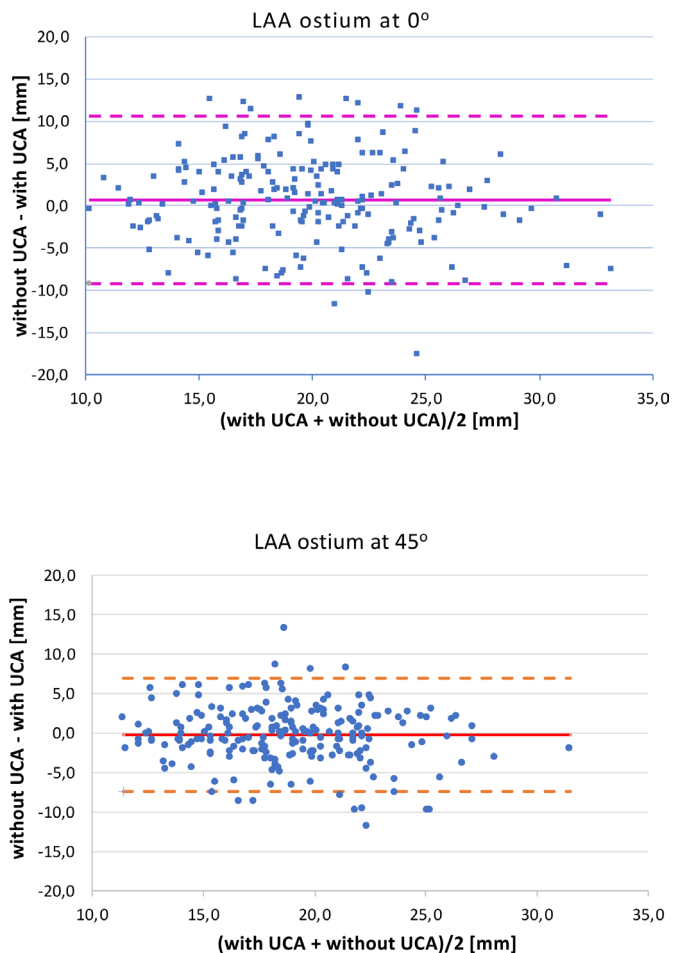


Figure 1 Bland-Altman plots for the quantification of the LAA ostium with and without the use of ultrasound contrast agent. LAA, left atrial appendage; UCA, ultrasound contrast agent.

measurements of the LAA ostium were repeated by a second investigator (table 3). When comparing the differences it turns out that the use of UCA rather leads to a higher variability between the two investigators than to an improved precision. This finding could be observed in three of the four standard views (45°, 90°, 135°).

It is known that in patients with a bilobar LAA morphology, both the diagnosis of LAA thrombi as well as the interventional LAAC might turn out to be challenging.^{5,6} Therefore, we especially determined whether the use of UCA is helpful in these cases. In our study, a bilobar LAA was found in 86 out of the 223 examinations. However, also in these cases, the application of UCA did not result in a better precision of the measurements (table 3).

DISCUSSION

Correct sizing of the LAA is of crucial importance during LAAC. To date, the predominant imaging modality to guide LAAC is TOE, although other imaging modalities like intracardiac echocardiography can be considered as an alternative leading to comparable clinical results.⁷

Table 3 Precision of size determination of the LAA ostium depending on the use of UCA in the total cohort of patients and in patients with bilobar LAA morphology, respectively

TOE view	Measured difference of LAA ostium without UCA (mm)	Measured difference of LAA ostium with UCA (mm)	P value
All patients (N=223)			
All views (N=715)	0.97±4.22	1.83±3.81	<0.001
0° (N=144)	1.35±5.01	1.42±4.48	0.871
45° (N=200)	0.42±3.62	1.54±3.29	<0.001
90° (N=199)	1.04±3.87	1.89±3.45	0.002
135° (N=172)	1.22±4.53	2.42±4.08	0.004
Patients with bilobar LAA (N=86)			
All views (N=305)	0.96±4.23	1.54±4.05	0.038
0° (N=63)	0.90±4.78	0.89±4.78	0.989
45° (N=84)	0.57±3.71	1.27±3.35	0.093
90° (N=83)	1.15±4.16	1.78±3.61	0.133
135° (N=75)	1.33±4.40	2.11±4.52	0.242

Shown are the differences of the size of the LAA ostium as measured by two independent operators with or without UCA. LAA, left atrial appendage; TOE, transoesophageal echocardiography; UCA, ultrasound contrast agent.

We and others have shown previously that the use of UCA during TOE can improve the rule out of thrombi in patients with AF^{4,8,9} which in our study led to a 38% reduction of the inadequate postponing of interventional procedures.⁴ However, so far there are no reports describing whether the use of UCA would also have an impact on the size determination of the LAA and whether UCA would perhaps increase the precision of LAA sizing in TOE.

It is a well-known fact that different imaging modalities often lead to systematic differences in the size determination of cardiac structures. For instance, sizing of the aortic anulus will systematically yield larger values if CT scan is used instead of echocardiography (review in van Gils *et al.*)¹⁰ Likewise, it has been shown that the size of the LAA orifice is systematically underestimated in 2D TOE in comparison to CT scan or 3D TOE, respectively.¹¹ One of our hypotheses for the study presented here was that a better delineation of the endocardial borders arising from the routine use of UCA during TOE might both have an impact on the size determination of the LAA as well as improve the precision of the measurements indicated by a reduced interobserver variability, respectively. However, after a detailed analysis of 223 prospective TOE examinations that were performed to evaluate the LAA in patients with AF, it turned out that UCA neither had an impact on the sizing of the LAA nor led to an increased precision of the measurements. On the contrary, interobserver variability was found to be significantly increased when UCA was applied.

It has to be mentioned that in our study, the image quality of the LAA was graded as poor in 15 out of 223 examinations (6.7%). In these examinations, the majority of measurements could not be taken so that the effect of UCA in these cases is difficult to judge.

Taken together, our study shows that although the use of UCA during TOE leads to an improved rule out of thrombi there is no advantageous effect of the UCA on the size determination of the LAA and should therefore not be used for this purpose.

Limitations

Our study has a number of limitations. Although the number of TOE examinations was considerably high (223 examinations), it was not possible to obtain images of all standard views for all individual patients. Additionally, all quantifications were performed in 2D but not in 3D datasets. In our study, the UCA had been administered as a single intravenous bolus according to the manufacturer's instructions; however, it might have been of advantage to use an infusion pump to reduce near field shielding. Due to the study design, no other imaging modalities such as CT scan could be included in the analyses.

Contributors HE: planning and conduct of the study, writing of the manuscript and responsible for the overall content. SG: planning and conduct of the study, data acquisition and manuscript revision. AW: data acquisition and manuscript revision. AO: conduct of the study, manuscript revision and data acquisition.

Funding This study was partially supported by a grant from Boston Scientific (Investigator Sponsored Research).

Competing interests HE has received honoraria for lectures from Bayer, Novartis, Pfizer, Boehringer Ingelheim and Boston Scientific.

Patient consent for publication Not required.

Ethics approval The study complies with the Declaration of Helsinki. Any necessary ethics committee approval was secured for the study reported. The research protocol has been approved by the Ethics Committee of the Medical Association of Thuringia and informed consent has been obtained from all subjects.

Provenance and peer review Not commissioned; externally peer reviewed.

Data availability statement Data are available upon reasonable request.

Open access This is an open access article distributed in accordance with the Creative Commons Attribution Non Commercial (CC BY-NC 4.0) license, which permits others to distribute, remix, adapt, build upon this work non-commercially, and license their derivative works on different terms, provided the original work is properly cited, appropriate credit is given, any changes made indicated, and the use is non-commercial. See: <http://creativecommons.org/licenses/by-nc/4.0/>.

ORCID iD

Henning Ebel <http://orcid.org/0000-0003-2465-1812>

REFERENCES

- 1 Klein AL, Grimm RA, Murray RD, *et al*. Use of transesophageal echocardiography to guide cardioversion in patients with atrial fibrillation. *N Engl J Med* 2001;344:1411–20.
- 2 Cresti A, García-Fernández MA, Sievert H, *et al*. Prevalence of extra-appendage thrombosis in non-valvular atrial fibrillation and atrial flutter in patients undergoing cardioversion: a large transoesophageal echo study. *EuroIntervention* 2019;15:e225–30.
- 3 Kirchhof P, Benussi S, Kotecha D, *et al*. 2016 ESC guidelines for the management of atrial fibrillation developed in collaboration with EACTS. *Rev Esp Cardiol* 2017;70:50.
- 4 Ebel H, Offhaus A, Wiora M, *et al*. Impact of ultrasound contrast agent on the detection of thrombi during transoesophageal echocardiography. *Open Heart* 2019;6:e001024.
- 5 Noutsias M, Melnyk H, Ali M, *et al*. Dual device closure of a bilobar left atrial appendage with a plug (Watchman 2.5™ 30 mm) and a pacifier (Amulet™ 20 mm) device. *Hellenic J Cardiol* 2020;137.
- 6 Mizuguchi KA, Burch TM, Bulwer BE, *et al*. Thrombus or bilobar left atrial appendage? diagnosis by real-time three-dimensional transesophageal echocardiography. *Anesth Analg* 2009;108:70–2.
- 7 Ribeiro JM, Teixeira R, Puga L, *et al*. Comparison of intracardiac and transoesophageal echocardiography for guidance of percutaneous left atrial appendage occlusion: a meta-analysis. *Echocardiography* 2019;36:1330–7.
- 8 Jung PH, Mueller M, Schuhmann C, *et al*. Contrast enhanced transesophageal echocardiography in patients with atrial fibrillation referred to electrical cardioversion improves atrial thrombus detection and may reduce associated thromboembolic events. *Cardiovasc Ultrasound* 2013;11:1.
- 9 Bernier M, Abdelmoneim SS, Stuart Moir W, *et al*. CUTE-CV: a prospective study of enhanced left atrial appendage visualization with microbubble contrast agent use during transesophageal echocardiography guided cardioversion. *Echocardiography* 2013;30:n/a–7.
- 10 van Gils L, Tchetché D, Latib A, *et al*. TAVI with current CE-marked devices: strategies for optimal sizing and valve delivery. *EuroIntervention* 2016;12:Y22–7.
- 11 Nucifora G, Faletra FF, Regoli F, *et al*. Evaluation of the left atrial appendage with real-time 3-dimensional transesophageal echocardiography: implications for catheter-based left atrial appendage closure. *Circ Cardiovasc Imaging* 2011;4:514–23.