

openheart Results of comprehensive diagnostic work-up in 'idiopathic' dilated cardiomyopathy

Kaspar Broch,^{1,2} Arne K Andreassen,¹ Einar Hopp,³ Trond P Leren,⁴ Helge Scott,⁵ Fredrik Müller,⁶ Svend Aakhus,¹ Lars Gullestad^{1,2}

To cite: Broch K, Andreassen AK, Hopp E, *et al*. Results of comprehensive diagnostic work-up in 'idiopathic' dilated cardiomyopathy. *Open Heart* 2015;**2**:e000271. doi:10.1136/openhrt-2015-000271

Received 24 March 2015
Revised 17 June 2015
Accepted 26 August 2015

ABSTRACT

Objective: Dilated cardiomyopathy (DCM) is characterised by left ventricular dilation and dysfunction not caused by coronary disease, valvular disease or hypertension. Owing to the considerable aetiological and prognostic heterogeneity in DCM, an extensive diagnostic work-up is recommended. We aimed to assess the value of diagnostic testing beyond careful physical examination, blood tests, echocardiography and coronary angiography.

Methods: From October 2008 to November 2012, we prospectively recruited 102 patients referred to our tertiary care hospital with a diagnosis of 'idiopathic' DCM based on patient history, physical examination, routine blood tests, echocardiography and coronary angiography. Extended work-up included cardiac MRI, exercise testing, right-sided catheterisation with biopsies, 24 h ECG and genetic testing.

Results: In 15 patients (15%), a diagnosis other than 'idiopathic' DCM was made based on additional tests. In 10 patients (10%), a possibly disease-causing mutation was detected. 2 patients were found to have non-compaction cardiomyopathy based on MRI findings; 2 patients had systemic inflammatory disease with cardiac involvement; and in 1 patient, cardiac amyloidosis was diagnosed by endomyocardial biopsy. Only in 5 cases did the results of the extended work-up have direct therapeutic consequences.

Conclusions: In patients with DCM, in whom patient history and routine work-up carry no clues to the aetiology, the diagnostic and therapeutic yield of extensive additional testing is modest.

INTRODUCTION

Dilated cardiomyopathy is characterised by left ventricular dilation and dysfunction in the absence of coronary disease, valvular disease or hypertension.¹ Approximately 20% of admittances for decompensated heart failure are due to dilated cardiomyopathy,² which probably represents the end-stage phenotype of almost any kind of global insult to the myocardium. Accordingly, the list of potential causes of dilated cardiomyopathy is long.¹ The diagnostic work-up is

KEY QUESTIONS

What is already known about this subject?

► Dilated cardiomyopathy probably represents the end-stage phenotype of almost any kind of global insult to the myocardium. There is a long list of potential causes, but more often than not, standard diagnostic test fail to reveal the aetiology of the disease. The patients are thus diagnosed with 'idiopathic' dilated cardiomyopathy, leaving the question of causality unanswered and the potential for tailored treatment unmet.

What does this study add?

► We show that extensive diagnostic testing beyond patient history, physical examination, routine blood tests, echocardiography and coronary angiography has a modest diagnostic yield and few therapeutic consequences. Testing for monogenic causes established possible aetiology in 10% of cases.

How might this impact on clinical practice?

► This paper provides information about the diagnostic and therapeutic consequences of a number of diagnostic tests in 'idiopathic' dilated cardiomyopathy. The value of diagnostics beyond routine testing in dilated cardiomyopathy must be weighted carefully against costs. Our results may help device diagnostic strategies in a large group of patients.

usually limited to physical examination, blood tests, echocardiography and coronary angiography.² More often than not, these tests fail to reveal the aetiology of the disease, and the patients are diagnosed with 'idiopathic' dilated cardiomyopathy.³ They then receive generic treatment for heart failure, leaving the question of causality unanswered and the potential for tailored treatment unmet in a disease with high mortality and morbidity.^{3,4}

Outcome in dilated cardiomyopathy depends on aetiology.³ Dilated cardiomyopathy caused by systemic inflammatory disease requires specific treatment, and some causes



CrossMark

For numbered affiliations see end of article.

Correspondence to

Dr Kaspar Broch;
kaspar.broch@ous-hf.no

of dilated cardiomyopathy predispose to malignant arrhythmia, strengthening the indication for cardioverter-defibrillator (ICD) implantation. Identification of a heritable cause allows for family screening, possibly allowing for early phenotype detection and appropriate treatment. Establishing the aetiology may thus influence the way we inform and treat patients with dilated cardiomyopathy.

In a seminal paper by Felker *et al.*³ an endomyocardial biopsy identified the underlying cause in 15% of patients referred to the Johns Hopkins Hospital for diagnostic evaluation of dilated cardiomyopathy. Over the recent years, imaging techniques have improved, and techniques for detecting monogenetic and viral causes have been introduced. The value of employing each of these modalities in patients with initially unexplained dilated cardiomyopathy, and in particular the value of a comprehensive, multimodality work-up, has not been systematically investigated. We aimed to evaluate the diagnostic yield and therapeutic consequences of a multimodality diagnostic investigation, beyond physical examination, echocardiography, coronary angiography and blood tests, in a contemporary cohort of patients with 'idiopathic' dilated cardiomyopathy. We assumed that a thorough diagnostic evaluation would yield an aetiological diagnosis in a substantial number of patients, with considerable impact on therapeutic and follow-up strategies.

MATERIALS AND METHODS

We report results from a prospective cohort study performed at our tertiary care university hospital. The trial complies with the Declaration of Helsinki and was approved by the Regional Committee for Medical and Health Research Ethics (REC South-East). All patients provided written, informed consent.

Patient population

The patient population has been described previously.⁵ In brief, we included consecutive patients aged 18 or above, admitted to our cardiology department with suspected dilated cardiomyopathy. Patients were required to have a left ventricular end diastolic internal diameter ≥ 6.5 cm (or an indexed value >3.2 cm/m²) and an ejection fraction $\leq 40\%$. Ischaemic, hypertensive and primary valvular heart disease were excluded by patient history, physical examination, angiography and echocardiography prior to inclusion. Patients with a known or suspected cause of cardiomyopathy, including acute or prior myocarditis; an implantable cardiac device; or severe concomitant disease were excluded. We did not exclude patients with well-controlled diabetes mellitus or well-controlled hypertension in the absence of concentric left ventricular hypertrophy.

Study procedures

At baseline, participants underwent physical examination; blood tests including screening for known

monogenic causes of dilated cardiomyopathy; echocardiography; cardiac MRI; ambulatory 24 h ECG; exercise testing with measurement of peak oxygen uptake and right-sided cardiac catheterisation with endomyocardial biopsy. One year after inclusion, the patients were reassessed. Patients were later followed-up through the Norwegian National Population Register and our heart transplant database for mortality and heart transplantation, respectively.

MRI

We used Siemens 1.5 T scanners for MRI (Siemens Avanto and Siemens Sonata; Siemens Medical Systems, Erlangen, Germany). Long and short axis images were acquired using a breath-hold, prospectively ECG-triggered, segmented, balanced steady-state free precession gradient-echo cine sequence with minimum echo and repetition times, 7 mm slice thickness, 4 mm short axis interslice gap, spatial resolution 1.9 mm \times 1.3 mm, and temporal resolution 30–35 ms. Left and right ventricular endocardial borders were traced manually at a PACS work station (Sectra Medical Systems AB, Linköping, Sweden). Ventricular volumes and ejection fractions were calculated by short axis slice summation.

Unless contraindicated due to renal insufficiency (estimated glomerular filtration rate <60 mL/kg/min/body surface area/1.73), images with late gadolinium enhancement (LGE) were acquired 10–20 min after intravenous injection of 0.2 mmol/kg of gadoterat meglumine (Guerbet, Villepinte, France). The total volume of late myocardial enhancement was quantified from visual analysis of short axis slices covering both ventricles.

Right-sided heart catheterisation

Right-sided heart catheterisation was performed using a Swan-Ganz pulmonary artery thermodilution catheter (Baxter Health Care Corp, Santa Ana, California, USA). Intracardiac pressures were recorded, and cardiac output was measured by the thermodilution technique. Endomyocardial biopsies were obtained from the right ventricular side of the myocardial septum for viral genome detection, and conventional and electron microscopy.

Viral genome detection

Total nucleic acid was extracted from endomyocardial biopsies. Detection of microbial nucleic acid was performed by real-time PCR, using in-house assays for adenovirus,⁶ human parvovirus B19⁷ and enterovirus,⁸ while commercial assays were used for Epstein-Barr virus (artus EBV, Qiagen, Hilden, Germany), human herpesvirus 6 (LightMix, TIB Molbiol, Berlin, Germany) and cytomegalovirus (Cobas Amplicor CMV monitor test, Roche, Branchburg, New Jersey, USA).

Conventional and electron microscopy

Endomyocardial specimens obtained for light microscopy were fixed with formalin, embedded in paraffin,

sliced into 5 µm sections, and stained with H&E as well as haematoxylin phloxine saffron and Congo stains for light microscopic examination.

Biopsy specimens scheduled for ultrastructural examination were fixed with glutaraldehyde and examined by electron microscopy.

Exercise testing and measurement of peak oxygen consumption

Maximal, upright, symptom-limited exercise testing was performed using an electrically braked bicycle ergo metre as previously described.⁵

Ambulatory 24 h ECG

Ambulatory 24 h ECGs were recorded with Medilog AR4 digital Holter monitors (Schiller AG, Baar, Switzerland) and edited in Medilog Excel V.3 by experienced nurses. The recordings were then reviewed by a physician, and mean, minimal and maximal heart rate; supraventricular arrhythmias (defined as at least five consecutive beats) and ventricular tachyarrhythmias (defined as three or more consecutive ventricular beats) were recorded. Pauses were defined as a temporal distance between two consecutive beats >1880 ms or >2380 ms after a ventricular premature beat.

Genetic testing

Blood samples for genetic analyses were obtained in all participants. DNA sequencing included the translated exons with flanking intron sequences of the genes MYH7, MYBPC3, MYL2, MYL3, TNNI3, TTNNT2, LMNA and ACTC. The pathogenicity of identified missense mutations was assessed with the bioinformatics software programs PolyPhen2 (<http://genetics.bwh.harvard.edu/pph2/>) and SIFT (<http://sift.jcvi.org/>).

Statistics

Values are presented as mean±SD or median (IQR) depending on distribution. Differences across subgroups were assessed by Student t tests for normally distributed values, Mann-Whitney U test for skewed parameters and χ^2 test for categorical data. Differences in the change in left ventricular ejection from baseline to follow-up were analysed by independent Student t tests. The effect of a variable on the time to death or heart transplantation was assessed by Cox regression analysis. All statistical analyses were performed with the Statistical Package for Social Sciences V.18 software (SPSS Inc, Chicago, Illinois, USA). Two-sided probability values were considered significant at $p<0.05$.

RESULTS

From the 13 of October 2008 to the 16 of November 2012, a total of 265 consecutive patients admitted to our tertiary care cardiology department were evaluated for participation (figure 1). One hundred and two patients fulfilled the inclusion criteria and were enrolled in the

current project. Their baseline data are presented in table 1.

By design, the results of coronary angiography, echocardiography and routine blood tests were not diagnostic of a specific cause of cardiomyopathy. Coronary angiography was performed in 101 patients, showing normal coronary arteries in 64 patients and discrete lesions in 37 patients. In one man, an 18-year-old man, coronary heart disease was excluded by CT angiography. The diagnostic yield and therapeutic consequences of additional testing are summarised in table 2.

MRI

Cardiac MRI was performed in 88 patients. Four patients had contraindications to MRI, and in 10 patients, it was not performed for administrative reasons. Two patients had a two-layered left ventricular myocardial structure and were diagnosed with non-compaction cardiomyopathy according to proposed criteria.⁹ These patients were subsequently treated with oral anticoagulation and ICDs. One of these patients received a cardiac allograft after 2.2 years, whereas the other was alive and transplant-free after 4.6 years' follow-up.

Seven patients were not exposed to gadolinium due to renal failure. In 29 of 81 patients receiving gadolinium, LGE was observed, with a median of 1.9 (0.8–3.0) % of left ventricular volume affected. Two patients had LGE of 24.6% and 45.1% of left ventricular volume, respectively, and a pattern of distribution suggestive of inflammatory cardiomyopathy. These patients were diagnosed with Wegener's granulomatosis and sarcoidosis, based on extracardiac and cardiac biopsy results, respectively. Both of these patients received appropriate immunosuppressive therapy, and after 5.3 and 4.7 years of follow-up, respectively, both were alive and transplant-free.

Right-sided cardiac catheterisation and endomyocardial biopsy

Right-sided cardiac catheterisation was performed in 101 patients (table 1); in one patient, an intraventricular thrombus represented a contraindication to the procedure. Endomyocardial biopsy was performed in 97/101 patients (96%). In two patients, access to the intraventricular septum was difficult, and endomyocardial biopsies were not obtained. In one patient, the procedure was prematurely terminated due to the development of haemopericardium, and in yet another patient, the endomyocardial material obtained was too sparse for diagnostic evaluation. In addition to the previously mentioned episode of per-procedural haemopericardium, another patient developed haemopericardium after the procedure. None of these patients developed signs of haemodynamic compromise, and pericardial drainage was not required. Nonetheless, the latter patient subsequently developed inflammatory pericarditis, successfully treated with corticosteroids.

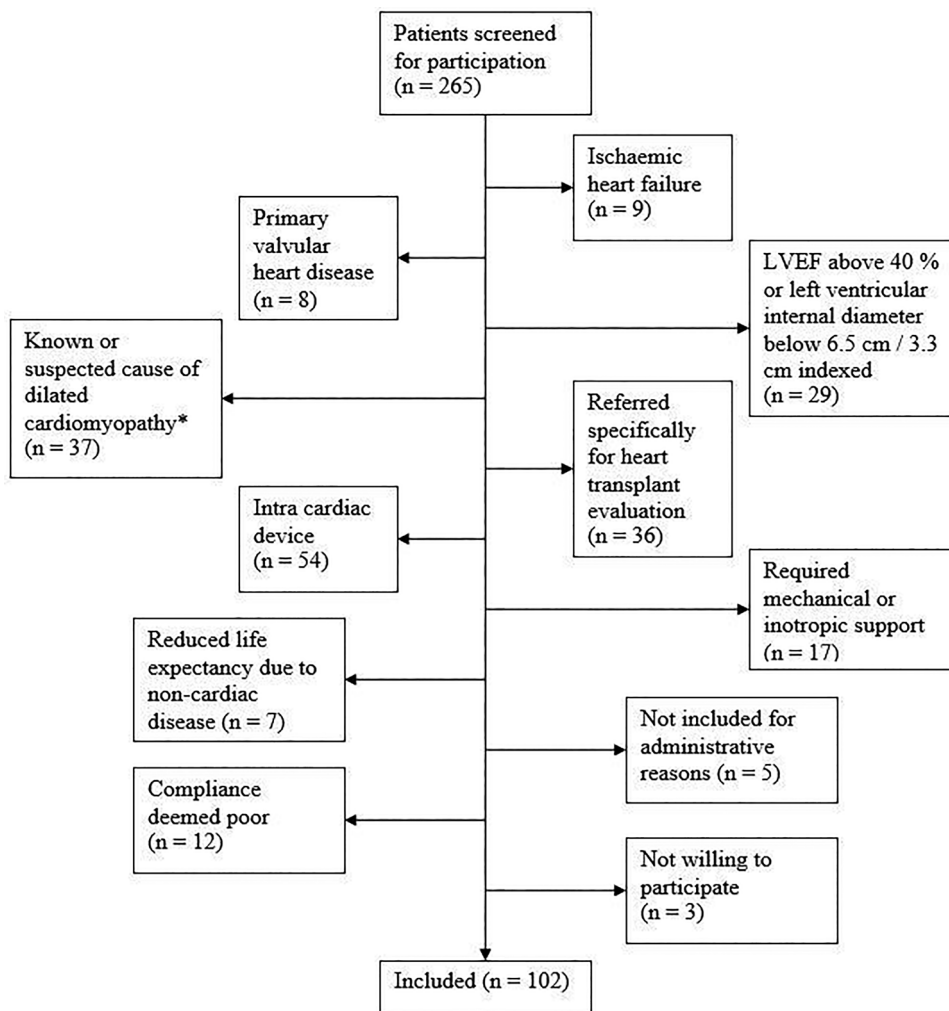


Figure 1 Patient selection. *This category included 10 patients with suspected tachyarrhythmia, 9 treated for cancer with cardiotoxic cytostatics and/or transthoracic irradiation, 7 patients with hypertensive disease and 11 others (LVEF, left ventricular ejection fraction).

Histology

Endomyocardial biopsies were assessed by conventional and electronic microscopy in 97 patients. A definitive diagnosis was made in two of these patients only. One patient had cardiac sarcoidosis as suspected on MRI, and one patient had (non-familial) transthyretin amyloidosis as confirmed by immune histochemistry. In the majority of patients, non-specific (N=82) or no (N=15) pathological findings were made.

Virus detection

In 16 patients, viral RNA/DNA was detected in the myocardium. Nine patients had persistent presence of parvovirus; four patients harboured adenoviral DNA; and three patients harboured human herpes virus 6 DNA. No patient had evidence of Epstein-Barr virus, cytomegalovirus or enteroviral persistence, and no patient had evidence of viral co-infection. There was no difference in the age (51 vs 52 years, $p=0.70$); gender distribution (63% vs 75% males, $p=0.30$); left ventricular ejection fraction (30% vs 26%; $p=0.17$); median

N-terminal pro-B-type natriuretic peptide (176 vs 155 pmol/L, $p=0.50$) or median C reactive protein (3.5 vs 3.0 mg/L, $p=0.71$) between patients with viral RNA/DNA and patients without evidence of viral persistence. Myocardial LGE was present in 8% of patients harbouring viral RNA/DNA, and in 40% of patients *without* evidence of viral persistence ($p=0.04$). In patients with viral RNA/DNA, left ventricular ejection fraction increased by $11\pm 13\%$ points over the first year, versus $15\pm 14\%$ points in patients without evidence of endomyocardial viral presence (p for difference 0.32). Viral persistence did not affect the risk of subsequent death or heart transplantation (HR=0.39 (95% CI 0.05 to 3.00), $p=0.36$).

Exercise testing with measurement of peak oxygen consumption

In three patients, one or more episodes of non-sustained ventricular tachycardia occurred during exercise testing. Two of these patients received ICDs, whereas in the third, β -blocker therapy was intensified. One of the two

Table 1 Population characteristics at inclusion (N=102)

Variable	
Clinical characteristics	
Age, years	51±14
Male gender, n (%)	74 (73)
Body mass index, kg/m ²	28±5
Systolic blood pressure, mm Hg	116±20
Diastolic blood pressure, mm Hg	71±12
Heart rate, bpm	75±16
Atrial fibrillation, n (%)	18 (18)
NYHA class (I/II/III/IV)	15/61/20/6
Medical history	
Smokers, n (%)	24 (24)
History of hypertension, n (%)	18 (18)
Diabetes mellitus prior to the development of heart failure, n (%)	4 (4)
Duration of symptoms, months	7 (3–16)
NYHA class at peak symptom severity (I/II/III/IV)	4/15/25/58
ECG	
QRS-duration, ms	110 (99–134)
Left bundle branch block, n (%)	21 (21)
Laboratory values	
Haemoglobin, g/dL	14.4±1.5
Creatinine, pmol/L	86±21
N-terminal pro-B-type natriuretic peptide, pg/mL	1332 (584–2903)
Echocardiography	
Left ventricular ejection fraction, %	26±10
Left ventricular end diastolic diameter, cm	7.1±0.8
Left ventricular end diastolic internal volume, mL	267 (216–328)
Cardiac output, L/min	4.9±1.4
Cardiac MRI (88 patients)	
Left ventricular ejection fraction, %	28±11
Left ventricular end diastolic internal volume, mL	273 (214–356)
Left ventricular myocardial volume, mL	212±62
Gadolinium late enhancement, n (%)	29 (35)
Exercise testing (96 patients)	
Maximum work load, W	133±56
Peak heart rate, bpm	151±25
Peak oxygen uptake, mL/kg/min	19.7±7
Peak oxygen uptake as percentage of expected value, %	69±22
Right-sided cardiac catheterisation (97 patients)	
Right atrial pressure, mm Hg	6 (4–10)
Mean pulmonary artery pressure, mm Hg	24±10
Pulmonary capillary wedge pressure, mm Hg	15±8
Cardiac output, L/min	4.9±1.5
24 h ECG (89 patients)	
Average heart rate, bpm	76±13
Minimum heart rate, bpm	49±10
Maximum heart rate, bpm	142±28
Ventricular tachycardia, n (%)	25 (28)

Values are presented as mean±SD or median (IQR) as appropriate.

patients who received an implantable cardiac defibrillator was later transplanted, whereas the other two were still alive and transplant-free 5.2 and 2.2 years after inclusion, respectively.

Ambulatory 24 h EGM

Twenty-four-hour ECGs were recorded in 89 patients (table 1). In 25 patients, one or more non-sustained ventricular tachycardias were recorded. Fifteen of these

patients subsequently received ICDs. After a median follow-up of 3.2 (2.2–4.5) years, 21 (84%) of the patients in whom non-sustained ventricular tachycardia had been detected were alive and transplant-free, whereas 3 patients were heart transplanted (all of whom had received ICDs) and 1 patient was dead due to traumatic head injury. Five patients had brief supraventricular tachycardias and 16 patients had pauses, none of which were deemed to be of clinical significance.

Table 2 Diagnostic yield and therapeutic consequences of additional testing in 'idiopathic' dilated cardiomyopathy

Diagnostic test	Diagnostic yield	Therapeutic consequences
Cardiac MRI	Two patients diagnosed with non-compaction cardiomyopathy	Oral anticoagulation initiated and ICDs implanted
MRI with gadolinium contrast	Two patients diagnosed with cardiomyopathy in association with systemic inflammatory disease	Appropriate immunosuppressant therapy initiated
Right-sided cardiac catheterisation	None	No direct therapeutic consequences. Haemodynamic data can be used to optimise diuretic treatment
Endomyocardial biopsy	Two patients diagnosed with cardiac sarcoidosis* and ATTR-amyloidosis, respectively	Patient with sarcoidosis treated with prednisone
Exercise test with measurement of peak oxygen consumption	None	Ventricular arrhythmia prompted ICD implantation in two patients. Peak oxygen consumption one of several parameters used in stratification for heart transplantation
Twenty-four-hour ECG	None	No direct consequences. Detection of non-sustained ventricular tachycardia strengthens the case for ICD implantation
Genetic screening	Ten patients diagnosed with possible disease-causing mutations	Finding prompted ICD implantation in one patient. Allowed for family screening

*This patient was also diagnosed on cardiac MRI with late gadolinium enhancement. ICD, implantable cardioverter-defibrillator.

Genetic screening

Genetic screening was performed in all patients. Twenty-four patients had a family history suggestive of familiar disease. In 10 patients, a possible disease-causing mutation was uncovered, four patients had a mutation in MYH7; three patients had a mutation in LMNA; one patient had a TNNT2 mutation; and two patients had a mutation in MYL3 (table 3). Notably, only three of these patients had a family history indicating familial dilated cardiomyopathy. In one patient, the detection of an LMNA mutation directly prompted the implantation of an ICD.

Two of the patients with a possibly disease-causing mutation received a cardiac allograft within 1 year after inclusion. In the eight transplant-free survivors, left ventricular ejection fraction increased by $10\pm 10\%$ points over the first year, versus $14\pm 13\%$ points in patients without a detectable, monogenic cause (p for difference 0.36). There was a trend towards a higher risk of death or heart transplantation in patients with possible monogenic aetiology (HR=3.3 (95% CI 0.9 to 12.4), $p=0.07$).

DISCUSSION

Despite a meticulous diagnostic investigation, we uncovered a specific aetiology in a limited number of patients with initially unexplained dilated cardiomyopathy. The therapeutic consequences of extensive testing were modest. It is important to bear in mind, however, that we present results from a selected patient cohort in whom patient history, routine laboratory work-up, echocardiography and coronary angiography provided no clue to the aetiology. Thus, our results reflect the

potential for extracting additional information after traditional diagnostic options have been exhausted.

The potential value of a diagnostic test in terms of prognostication or adjusted treatment must be weighed against monetary costs and complications. Cardiac MRI offers unparalleled image clarity and detail, but its widespread use is limited by availability, tolerability and costs. Endomyocardial biopsy incurs patient discomfort and moderate risk and is recommended only in patients presenting with severe heart failure and a very short duration of symptoms, failure to respond to treatment or associated ventricular arrhythmia.¹³ Twenty-four-hour ECG and cardiopulmonary exercise testing are low-cost, low-risk procedures, but the diagnostic and therapeutic yield is difficult to quantify.

MRI identified two cases of non-compaction cardiomyopathy not detected by echocardiography. Non-compaction cardiomyopathy is defined as a distinct entity in an 'unclassified' group of cardiomyopathies.¹ However, it is unclear whether non-compaction cardiomyopathy is truly a separate disease, or merely a morphological trait shared by many cardiomyopathies.^{1 14} The diagnosis is usually made by echocardiography, but non-compaction cardiomyopathy can be difficult to differentiate from other causes of heart failure,¹⁵ with several proposed echocardiographic diagnostic criteria coexisting. MRI may offer better diagnostic sensitivity and specificity in this disease.⁹ Owing to a high risk of ensuing heart failure, thromboembolic events and arrhythmia,^{16 17} the use of oral anticoagulants and a low threshold for the implantation of an intracardiac defibrillator has been advocated in patients with non-compaction cardiomyopathy.

Table 3 Mutations identified as possible causes of dilated cardiomyopathy

Gene	Mutation	Bioinformatics information		Disease-causing	Previously reported
		PolyPhen2	SIFT		
LMNA	c.642delG (p.E214DfsX266)	—	—	Definitely (premature stop codon)	No
LMNA	c.886–887insA (p.R296QfsX35)	—	—	Definitely (premature stop codon)	No
LMNA	c.986G>A (p.R329H)	Benign	Not tolerated	Possibly	No
MYH7	c.2945T>C (p.M982T)	Probably damaging	Not tolerated	Probably	Yes ¹⁰
MYH7	c.3818T>C (p.L1273P)	Probably damaging	Not tolerated	Probably	Yes ¹¹
MYH7	c.4076G>A (p.R1359H)	Probably damaging	Not tolerated	Probably	No
MYH7	c.5287G>A (p.A1763T)	Possibly damaging	Not tolerated	Probably	Yes ¹¹
TNNI2	c.421delC (p.R141GfsX41)	—	—	Definitely (premature stop codon)	Yes ¹²
MYL3	c.65C>T (p.A22V)	Benign	Not tolerated	Possibly	No
MYL3	c.400G>T (p.V134L)	Benign	Tolerated	Possibly not	No

The reference sequences used for nucleotide numbering are LMNA: NM_005572.3, MYH7: NM_000257.2, TNNI2: NM_001001430.1 and MYL3: NM_000258.2.

The use of LGE allows for the detection of ischaemia, fibrosis and inflammation by MRI.¹⁸ Unfortunately, gadolinium can induce nephrogenic systemic sclerosis in patients with renal failure, and its use is contraindicated in these patients.¹⁹ In approximately one-third of our patients, LGE was observed. Two cases of systemic inflammatory disease with cardiac involvement were discovered using this technique. Survival in patients with systemic inflammatory diseases and associated cardiomyopathy is on average lower than in idiopathic dilated cardiomyopathy,³ but depends on the category of the underlying disease.²⁰ The therapeutic consequence of making a diagnosis of systemic inflammatory disease in these patients is substantial, as treatment is targeted at the underlying disease as well as the cardiac manifestations.

In our cohort, only one diagnosis made by endomyocardial biopsy did have therapeutic consequences. This patient had sarcoidosis, whereas a case of Wegener's granulomatosis was missed on endomyocardial biopsy, probably due to patchy myocardial involvement. One patient was diagnosed with non-familial ATTA (transthyretin) amyloidosis, but for this condition, there is no specific treatment, and the prognosis is fair.²¹

Recent studies have indicated that as many as 50% of patients with 'idiopathic' dilated cardiomyopathy may have familial disease.^{22–23} Mutations in many different genes have been shown to cause dilated cardiomyopathy,²⁴ most commonly with an autosomal dominant pattern of inheritance.²² Owing to incomplete penetrance and variable expressivity within families, the hereditary nature of the disease may easily escape detection.²² The mutations causing dilated cardiomyopathy that have been described so far, account for only a minority of the cases thought to be hereditary on the basis of their familial occurrence.²³ Genetic screening provided a moderate diagnostic return in our patient population, uncovering 10 cases with possibly pathogenic mutations. These findings allowed for familial cascade screening,²⁵ potentially allowing for early treatment of subclinical phenotype expression. However, the clinical effect of early treatment in these cases remains unknown. The trend towards a worse prognosis in patients with a monogenic aetiology suggests that these patients should be followed closely.

Some cases of dilated cardiomyopathy are thought to occur secondary to myocarditis.²⁶ Viral RNA/DNA has been detected in the myocardium of a large proportion of patients with dilated cardiomyopathy,^{27–28} and viral persistence may be associated with a poor prognosis.²⁹ However, the clinical significance of myocardial viral RNA/DNA presence is under debate, and studies have demonstrated a high prevalence of viral presence in the myocardium of persons with no evidence of heart disease.³⁰ We did not find that patients with viral RNA/DNA detectable on endomyocardial biopsy differed significantly from patients without evidence of viral presence in the myocardium.

In everyday practice, we combine results from many diagnostic modalities to tailor treatment in patients with heart failure. Above, we have summarised the direct yield of specific diagnostic test. In addition, we use haemodynamic parameters from cardiac catheterisation to optimise diuretic treatment, we use results obtained by 24 h ECG to tailor antiarrhythmic treatment, and we use peak oxygen consumption to stratify patients for heart transplantation. The combined therapeutic yield of this information is, however, difficult to quantify.

Limitations

We present a carefully examined, but small-to-medium-sized material from a tertiary high-volume university hospital. Our patient population may differ from the population of patients with 'idiopathic' dilated cardiomyopathy encountered at local hospitals or in general practice. Contraindications, technical difficulties and a very few complications precluded some diagnostic test from being performed or analysed. This probably represents a 'real-life situation', but we cannot exclude the possibility that a few more aetiological diagnoses could have been made had every diagnostic test been performed in every patient.

CONCLUSION

In our cohort of patients with dilated cardiomyopathy, in whom patient history and routine work-up carried no clues to the aetiology of their disease, the diagnostic and therapeutic yield of extensive additional testing was moderate. Testing for monogenic causes established possible aetiology in 10% of cases. Cardiac MRI should probably be considered in selected cases guided by patient history, or when echocardiographic assessment is difficult due to poor sonographic imaging conditions. Our results support a restrictive use of endomyocardial

Author affiliations

¹Department of Cardiology, Oslo University Hospital Rikshospitalet, Oslo, Norway

²Faculty of Medicine, K.G. Jebsen Cardiac Research Centre and Center for Heart Failure Research, University of Oslo, Oslo, Norway

³Department of Radiology and Nuclear Medicine, Oslo University Hospital Rikshospitalet, Oslo, Norway

⁴Department of Medical Genetics, Oslo University Hospital Rikshospitalet, Oslo, Norway

⁵Institute of Pathology, Oslo University Hospital Rikshospitalet, Oslo, Norway

⁶Department of Microbiology, Oslo University Hospital Rikshospitalet, Oslo, Norway

Acknowledgements The authors would like to thank Wenche Stueflotten and Mai Britt Solberg for their invaluable contribution to data collection and interpretation.

Contributors KB has contributed to study design, acquisition, analysis and interpretation of data, drafting the article, and final approval of the article. AKA, EH, TPL, HS and FM have contributed to the acquisition, analysis and interpretation of data, revising the article for important intellectual content, and final approval of the article. SA and LG have contributed to study design, acquisition, analysis and interpretation of data, supervision, revising the article

for important intellectual content, and final approval of the article. All authors are accountable for all aspects of the work and take responsibility for the accuracy and integrity of the work.

Funding This work was supported by an unrestricted grant from Inger and John Fredriksen to the Department of Cardiology, Oslo University Hospital, Rikshospitalet.

Competing interests None declared.

Ethics approval The Norwegian Regional Committee for Medical and Health Research Ethics (REC South-East).

Provenance and peer review Not commissioned; externally peer reviewed.

Data sharing statement Additional unpublished data from the study can be obtained from the corresponding author on request.

Open Access This is an Open Access article distributed in accordance with the Creative Commons Attribution Non Commercial (CC BY-NC 4.0) license, which permits others to distribute, remix, adapt, build upon this work non-commercially, and license their derivative works on different terms, provided the original work is properly cited and the use is non-commercial. See: <http://creativecommons.org/licenses/by-nc/4.0/>

REFERENCES

- Elliott P, Andersson B, Arbustini E, *et al.* Classification of the cardiomyopathies: a position statement from the European Society Of Cardiology Working Group on Myocardial and Pericardial Diseases. *Eur Heart J* 2008;29:270–6.
- Nieminen MS, Brutsaert D, Dickstein K, *et al.* EuroHeart Failure Survey II (EHFS II): a survey on hospitalized acute heart failure patients: description of population. *Eur Heart J* 2006;27:2725–36.
- Felker GM, Thompson RE, Hare JM, *et al.* Underlying causes and long-term survival in patients with initially unexplained cardiomyopathy. *N Engl J Med* 2000;342:1077–84.
- Dec GW, Fuster V. Idiopathic dilated cardiomyopathy. *N Engl J Med* 1994;331:1564–75.
- Broch K, Andreassen AK, Ueland T, *et al.* Soluble ST2 reflects hemodynamic stress in non-ischemic heart failure. *Int J Cardiol* 2015;179:378–84.
- Heim A, Ebnet C, Harste G, *et al.* Rapid and quantitative detection of human adenovirus DNA by real-time PCR. *J Med Virol* 2003;70:228–39.
- Schalasta G, Schmid M, Lachmund T, *et al.* LightCycler consensus PCR for rapid and differential detection of human erythrovirus B19 and V9 isolates. *J Med Virol* 2004;73:54–9.
- Kares S, Lonnrot M, Vuorinen P, *et al.* Real-time PCR for rapid diagnosis of entero- and rhinovirus infections using LightCycler. *J Clin Virol* 2004;29:99–104.
- Petersen SE, Selvanayagam JB, Wiesmann F, *et al.* Left ventricular non-compaction: insights from cardiovascular magnetic resonance imaging. *J Am Coll Cardiol* 2005;46:101–5.
- Morita H, Larson MG, Barr SC, *et al.* Single-gene mutations and increased left ventricular wall thickness in the community: the Framingham Heart Study. *Circulation* 2006;113:2697–705.
- Berge KE, Leren TP. Genetics of hypertrophic cardiomyopathy in Norway. *Clin Genet* 2014;86:355–60.
- Millat G, Bouvagnet P, Chevalier P, *et al.* Clinical and mutational spectrum in a cohort of 105 unrelated patients with dilated cardiomyopathy. *Eur J Med Genet* 2011;54:e570–5.
- Cooper LT, Baughman KL, Feldman AM, *et al.* The role of endomyocardial biopsy in the management of cardiovascular disease: a scientific statement from the American Heart Association, the American College of Cardiology, and the European Society of Cardiology. *Circulation* 2007;116:2216–33.
- Almeida AG, Pinto FJ. Non-compaction cardiomyopathy. *Heart* 2013;99:1535–42.
- Kohli SK, Pantazis AA, Shah JS, *et al.* Diagnosis of left-ventricular non-compaction in patients with left-ventricular systolic dysfunction: time for a reappraisal of diagnostic criteria? *Eur Heart J* 2008;29:89–95.
- Oechslin EN, Attenhofer Jost CH, Rojas JR, *et al.* Long-term follow-up of 34 adults with isolated left ventricular noncompaction: a distinct cardiomyopathy with poor prognosis. *J Am Coll Cardiol* 2000;36:493–500.
- Aras D, Tufekcioglu O, Ergun K, *et al.* Clinical features of isolated ventricular noncompaction in adults long-term clinical course,

- echocardiographic properties, and predictors of left ventricular failure. *J Card Fail* 2006;12:726–33.
18. Silva MJ, Pinto FJ. Clinical use of multimodality imaging in the assessment of dilated cardiomyopathy. *Heart* 2015;101:565–72.
 19. Grobner T, Prischl FC. Gadolinium and nephrogenic systemic fibrosis. *Kidney Int* 2007;72:260–4.
 20. Leyngold I, Baughman K, Kasper E, *et al.* Comparison of survival among patients with connective tissue disease and cardiomyopathy (systemic sclerosis, systemic lupus erythematosus, and undifferentiated disease). *Am J Cardiol* 2007;100:513–17.
 21. Ng B, Connors LH, Davidoff R, *et al.* Senile systemic amyloidosis presenting with heart failure: a comparison with light chain-associated amyloidosis. *Arch Intern Med* 2005;165:1425–9.
 22. Burkett EL, Hershberger RE. Clinical and genetic issues in familial dilated cardiomyopathy. *J Am Coll Cardiol* 2005;45:969–81.
 23. Fatkin D, Graham RM. Molecular mechanisms of inherited cardiomyopathies. *Physiol Rev* 2002;82:945–80.
 24. Lopes LR, Elliott PM. A straightforward guide to the sarcomeric basis of cardiomyopathies. *Heart* 2014;100:1916–23.
 25. Caleshu C, Day S, Rehm HL, *et al.* Use and interpretation of genetic tests in cardiovascular genetics. *Heart* 2010;96:1669–75.
 26. Liu PP, Mason JW. Advances in the understanding of myocarditis. *Circulation* 2001;104:1076–82.
 27. Pauschinger M, Bowles NE, Fuentes-Garcia FJ, *et al.* Detection of adenoviral genome in the myocardium of adult patients with idiopathic left ventricular dysfunction. *Circulation* 1999;99:1348–54.
 28. Lotze U, Egerer R, Tresselt C, *et al.* Frequent detection of parvovirus B19 genome in the myocardium of adult patients with idiopathic dilated cardiomyopathy. *Med Microbiol Immunol* 2004;193:75–82.
 29. Kuhl U, Pauschinger M, Seeberg B, *et al.* Viral persistence in the myocardium is associated with progressive cardiac dysfunction. *Circulation* 2005;112:1965–70.
 30. Corcioli F, Zakrzewska K, Rinieri A, *et al.* Tissue persistence of parvovirus B19 genotypes in asymptomatic persons. *J Med Virol* 2008;80:2005–11.